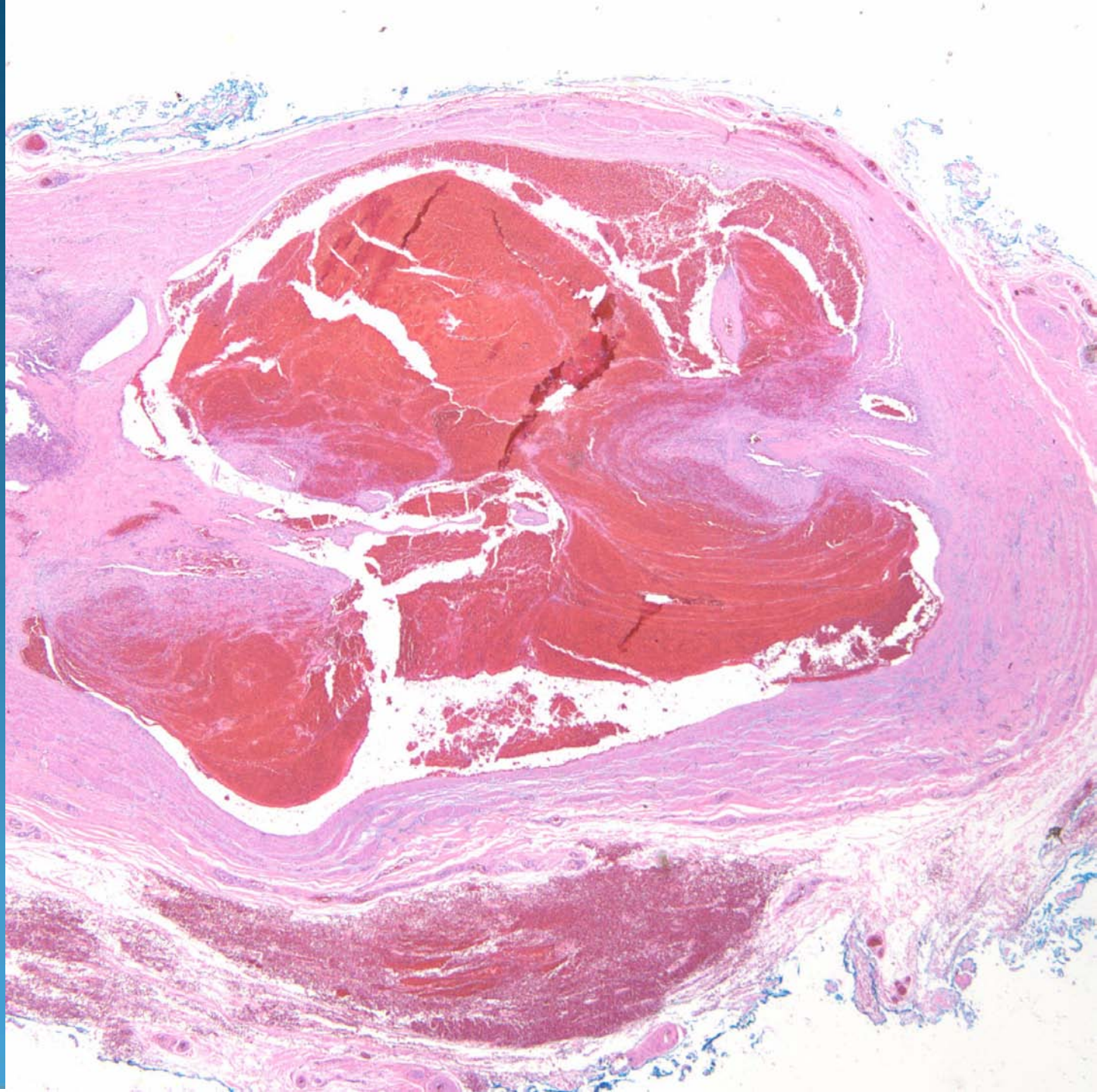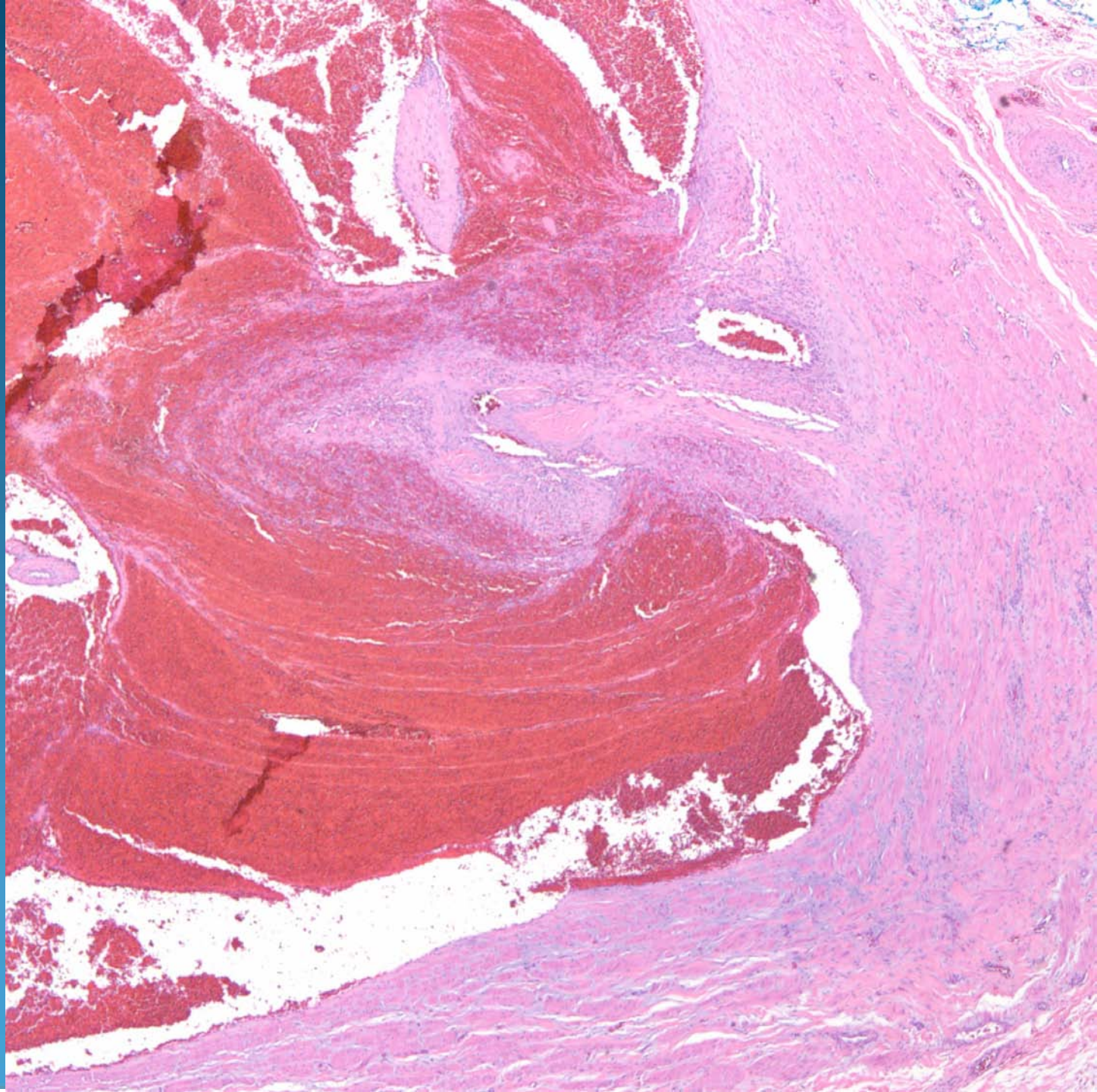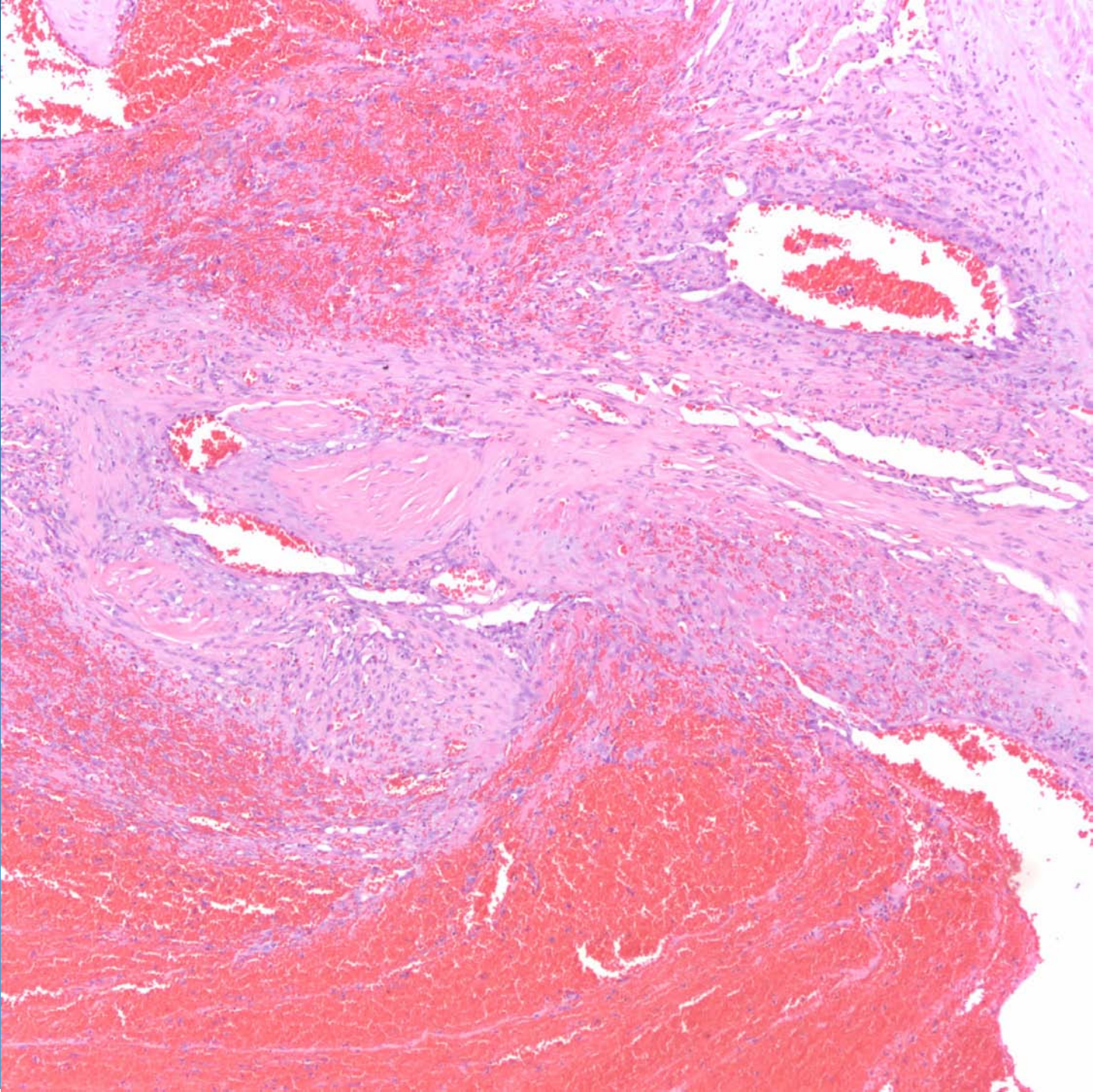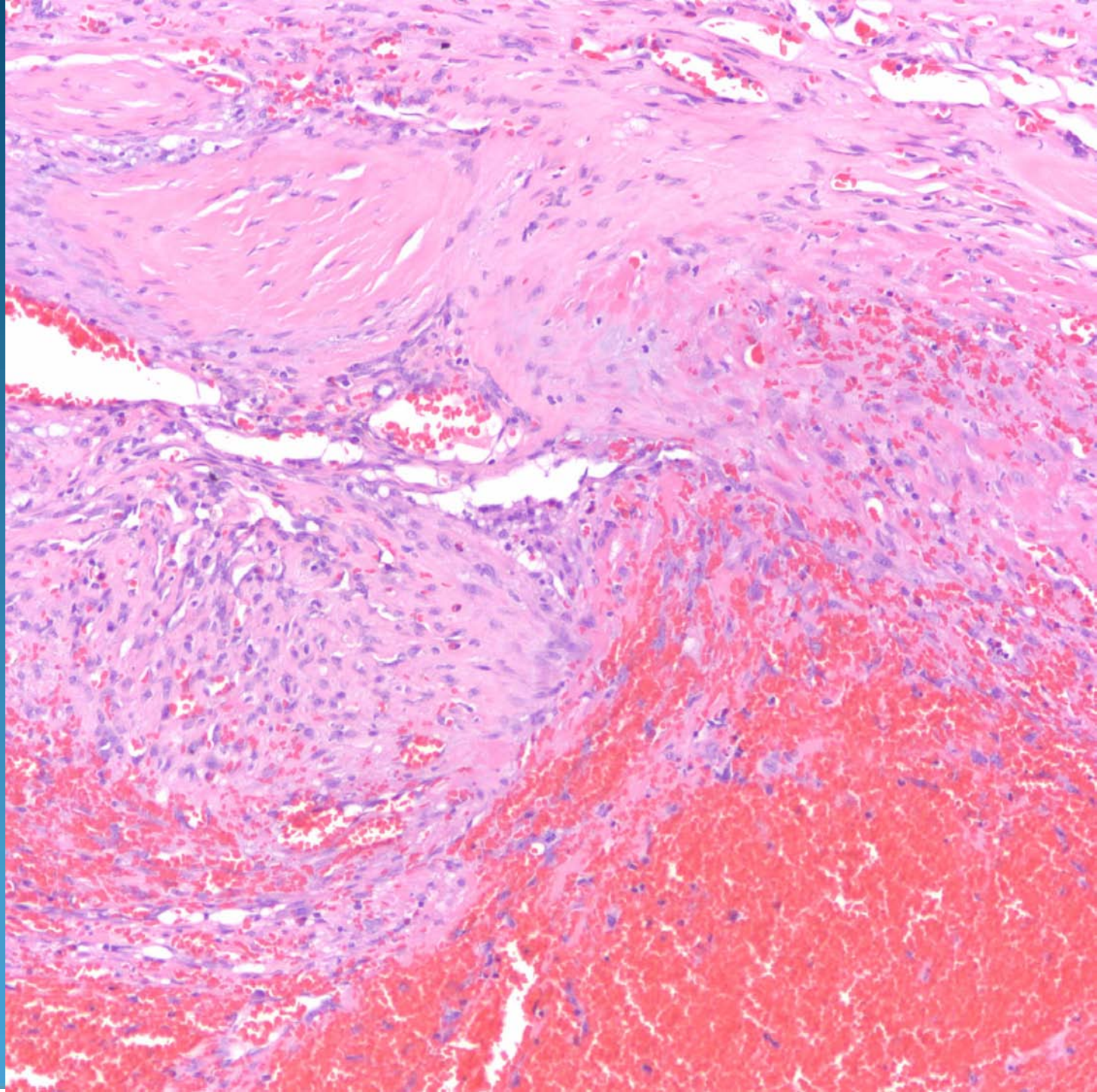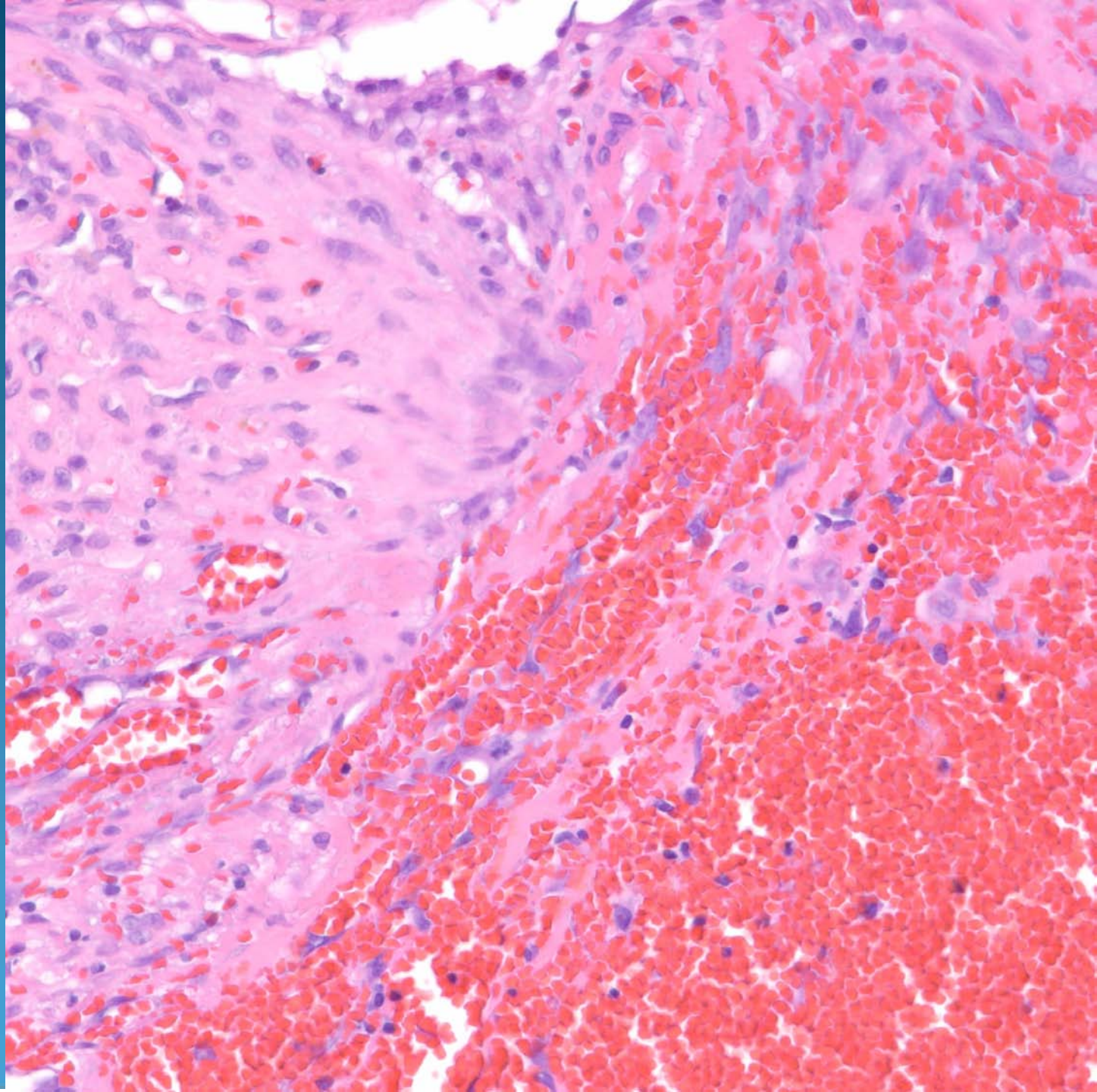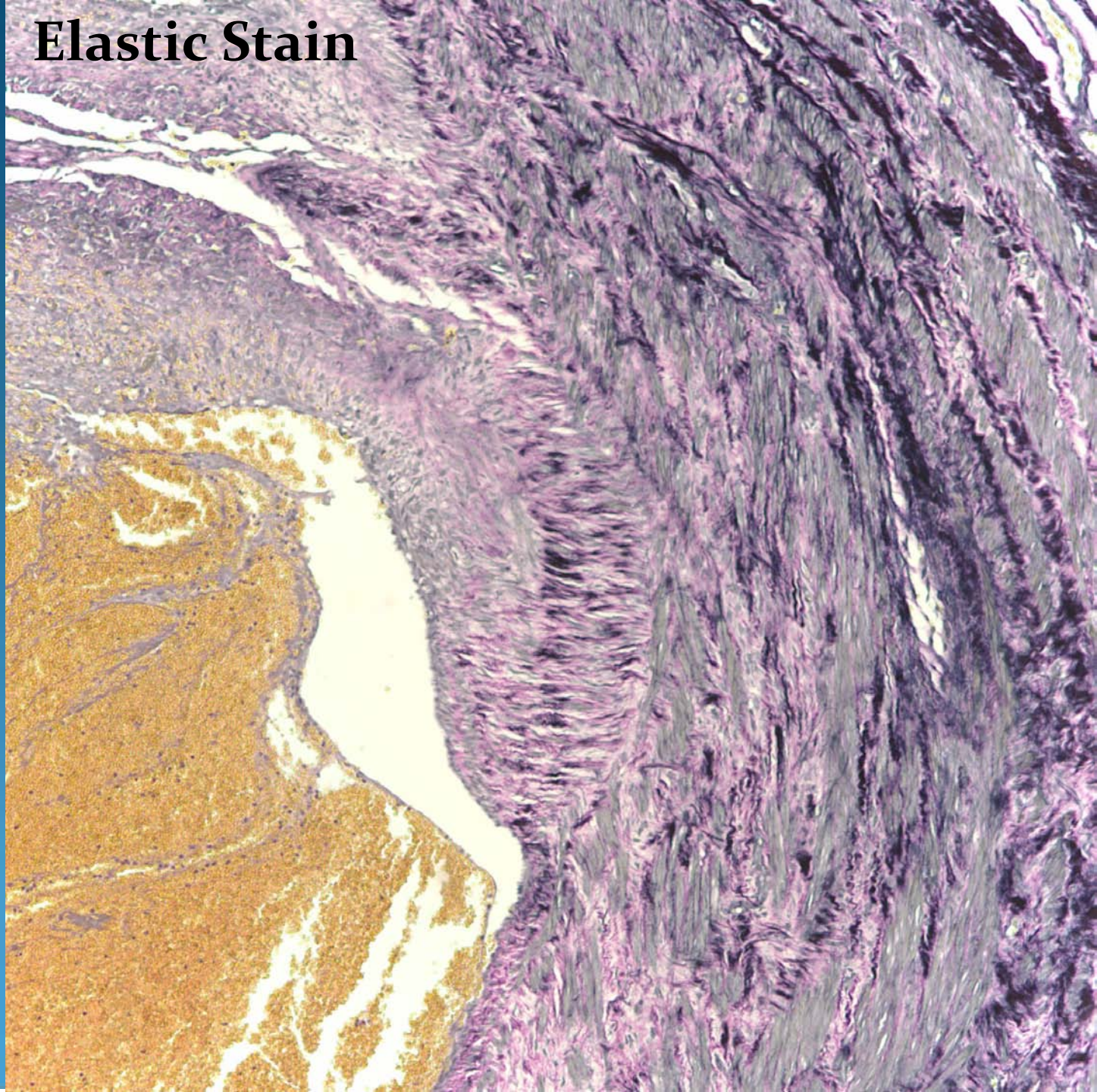
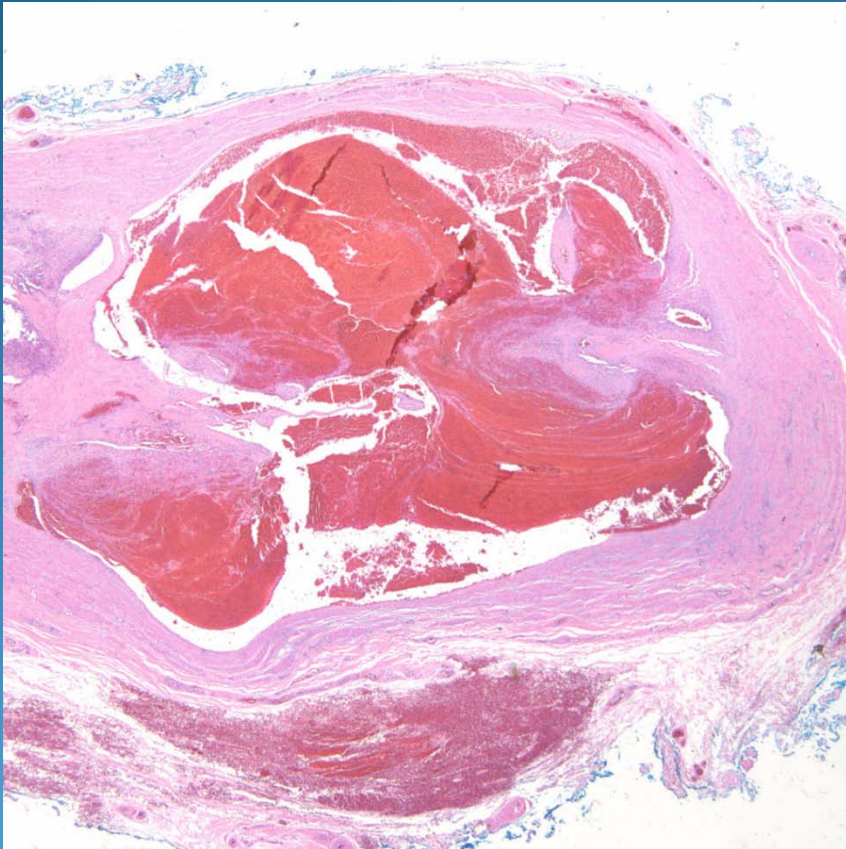


Organizing Thrombus

Elastic Stain



Pearls



- Look for ectatic vascular space-may confirm vascular wall with elastic stain
- Thrombus will be attached to intimal lining
- Degree of organization dependent upon age of thrombus